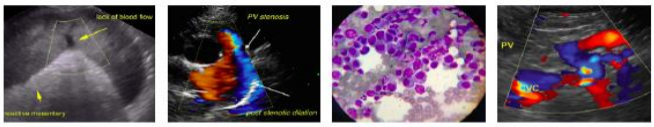

SonoPath.com
1-800-838-4268 info@sonopath.com

PATIENT

Lucy Ongsitco

SPECIES

Canine

BREED

English Bulldog

SEX

MN

AGE

11½ years

WEIGHT

36 #

INTERPRETED BY

Remo Lobetti, BVSc, MMedVet (Med), PhD, Dipl. ECVIM

IMAGING PERFORMED BY

Dr Megan Cassels-Conway, DVM

HOSPITAL NAME

Central Broward Animal Hospital

REFERRING VET

Dr Oms, DVM

INVOICE

303147

DATE

7/27/22

PRESENTING CLINICAL SIGNS

History: Severe intermittent chronic diarrhea – on home cooked diet and probiotics.

Physical Examination: N/A.

Urinalysis: SG 1.036, negative sediment.

Fecal Analysis: Pending.

CBC: Thrombocytosis.

Serum Biochemistry: Hypoalbuminemia. Maldigestion profile pending.

Radiographic Findings: Normal.

ULTRASONOGRAPHIC EXAMINATION OF THE ABDOMEN

Urinary System

Full urinary bladder with a normal thickness and appearance of the wall. Normal anechoic urine with no sediment or uroliths evident.

Normal trigone area, proximal urethra, and iliac blood vessels.

Normal iliac lymph nodes. Ureters not visualized.

Normal renal size (left 5.6 cm, right 5.5 cm), echogenic appearance, cortico-medullary differentiation, pelvis, and capsule.

Reproductive System

N/A.

Adrenal Glands

Normal shape, echogenic appearance, position, and size. Left 2.29 x 0.61 cm, right 1.86 x 0.57 cm.

Spleen

Normal size and echogenic appearance. Smooth homogenous parenchyma, regular curvilinear capsule, and normal vasculature. No evidence of inflammatory, neoplastic, infarction, or infiltrative changes noted. Incidental myelolipoma

Liver

Normal size, echogenic appearance, portal markings, and curvilinear capsule. No nodules or masses evident. Full gall bladder containing small amount of hyperechogenic sediment. Normal appearance and thickness of the gall bladder wall. Normal bile duct.

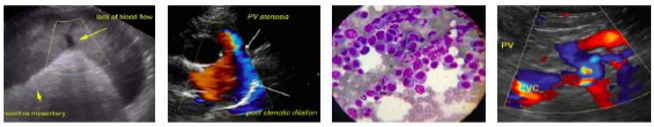

SonoPath.com
1-800-838-4268 info@sonopath.com

PATIENT

Lucy Ongsitco

SPECIES

Canine

BREED

English Bulldog

SEX

MN

AGE

11½ years

WEIGHT

36 #

INTERPRETED BY

Remo Lobetti, BVSc, MMedVet (Med), PhD, Dipl. ECVIM

IMAGING PERFORMED BY

Dr Megan Cassels-Conway, DVM

HOSPITAL NAME

Central Broward Animal Hospital

REFERRING VET

Dr Oms, DVM

INVOICE

303147

DATE

7/27/22

Gastrointestinal

Normal appearance of the stomach, ileo-cecal junction, and colon with no loss of layering, normal wall thickness and peristaltic activity, and no distension of the lumen. Thickening of the duodenum and small intestine (0.62 cm) with a prominent hypoechogenic appearance of the submucosal layer with patchy areas of subtle mucosal stippling but no loss of layering or distension of the lumen and normal peristalsis. Ingesta within the small intestine.

Pancreas

Normal size and echogenic appearance. Normal echogenic appearance of the mesentery and fat surrounding the pancreas.

Free Abdomen

No mesenteric lymphadenomegaly.
Small amount of acellular ascites.

ULTRASONOGRAPHIC FINDINGS

Primary Findings:

- Enteropathy.
- Ascites.

Secondary Findings:

- Gall bladder sediment.

INTERPRETATION OF THE FINDINGS & FURTHER RECOMMENDATIONS

Etiologies for the enteropathy would be lymphangectasia, inflammatory bowel disease, dietary hypersensitivity, granulomatous enteritis, and parasitic enteritis.

The ascites can be ascribed to the enteropathy and hypoalbuminemia.

Further assessment/therapy needs to be based on the pending results, although endoscopy of the upper GI tract with biopsies would be recommended.

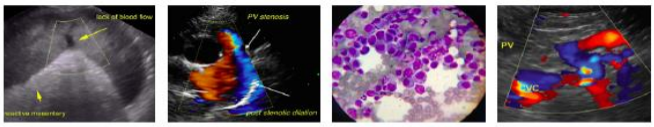

SonoPath.com
1-800-838-4268 info@sonopath.com

PATIENT

Lucy Ongsitco

SPECIES

Canine

BREED

English Bulldog

SEX

MN

AGE

11½ years

WEIGHT

36 #

INTERPRETED BY

Remo Lobetti, BVSc, MMedVet (Med), PhD, Dipl. ECVIM

IMAGING PERFORMED BY

Dr Megan Cassels-Conway, DVM

HOSPITAL NAME

Central Broward Animal Hospital

REFERRING VET

Dr Oms, DVM

INVOICE

303147

DATE

7/27/22

IMAGES

Small intestine

Ascites

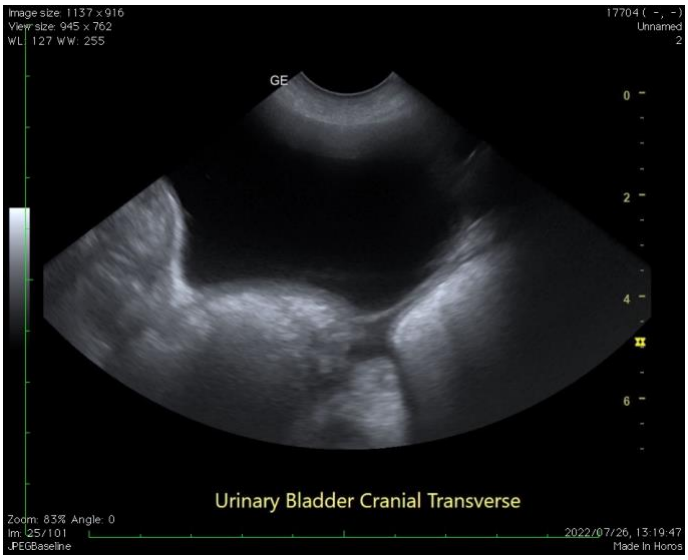

The information and recommendations provided are based on the images presented by the referring veterinarian. No evaluation can be communicated regarding pathology that was not visible in the image/video clips provided.

Thank you for this referral. If the clinical or image interpretation does not parallel your findings or if I can be of any further assistance, please contact me.

Remo Lobetti, BVSc, MMedVet (Med), PhD, Dipl. ECVIM (Internal Medicine)
rlobetti@mweb.co.za